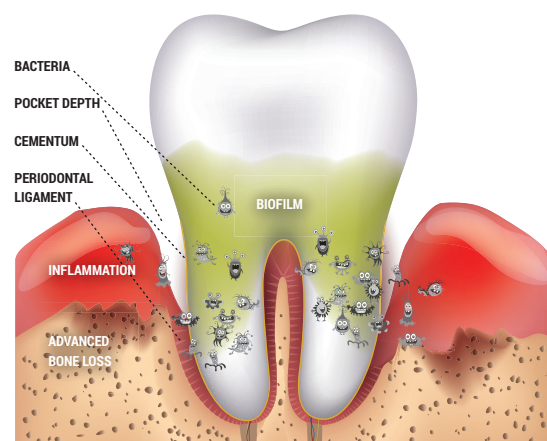


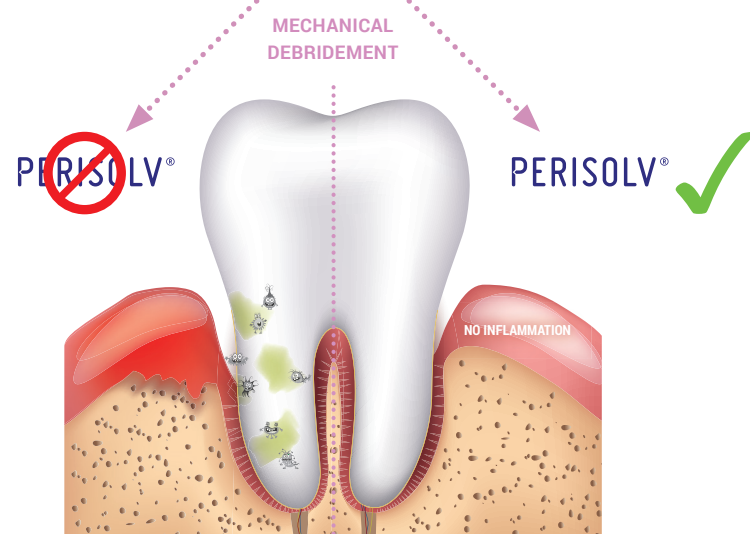
MODE OF ACTION

MECHANICAL DEBRIDEMENT ALONE OR WITH PERISOLV®

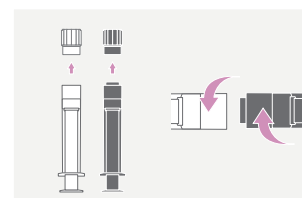
BEFORE



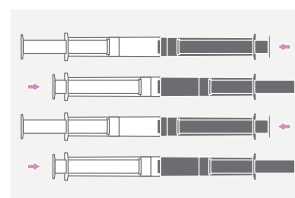
AFTER



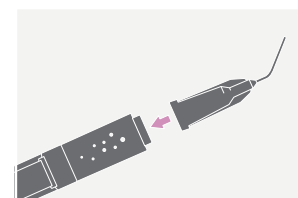
SIMPLE APPLICATION



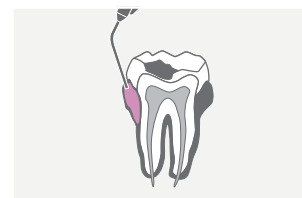
1. CONNECT



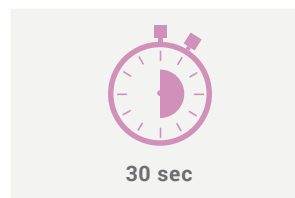
2. MIX



3. CANNULA

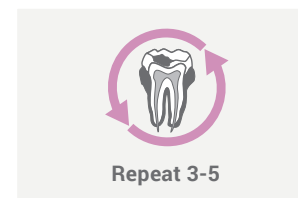


4. APPLY



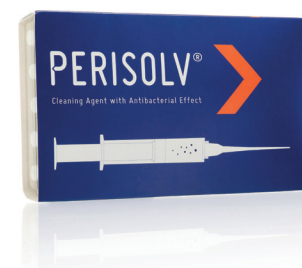30 sec

5. WAIT



Repeat 3-5

6. START



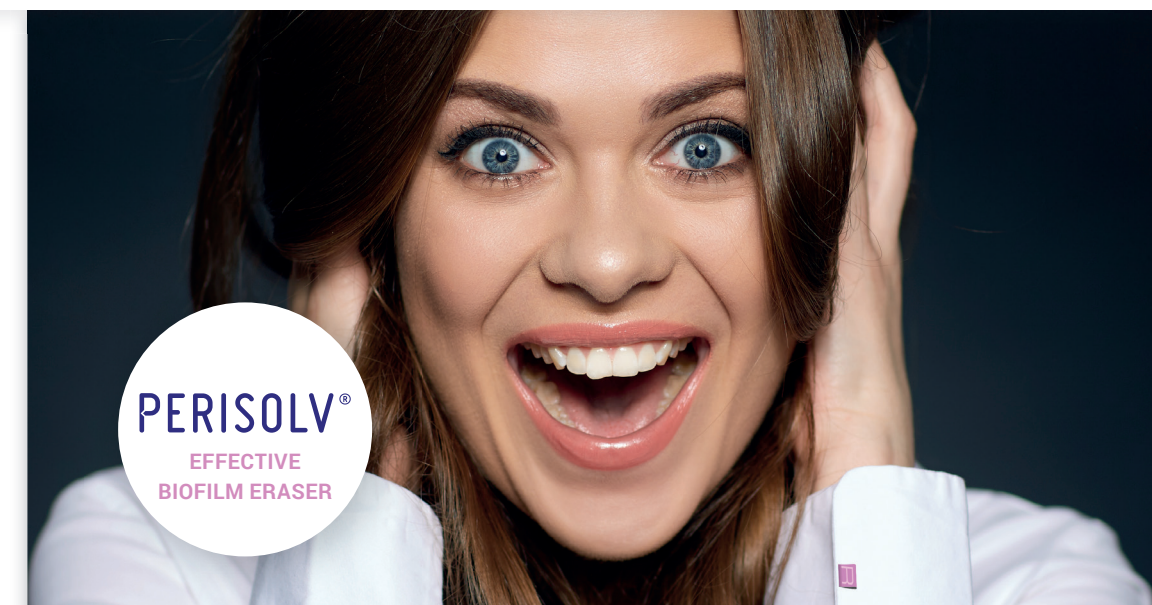LITERATURE

1. Data on file.
2. Guarnelli ME et al. 'Professional local administration of chloramine-based treatment in conjunction with ultrasonic mechanical instrumentation: clinical outcomes in patients with deep periodontal pockets persisting following active non-surgical therapy'. Minerva Stomatologia, April 2015; Vol. 64 suppl. 1 al No. 2: 158-159.
3. Data on file.

PERISOLV® is a registered trademark and is manufactured by RLS Global AB, Neongatan 5, SE-431 53 Mölndal.

MORE CLINICAL CASES AVAILABLE AT
www.regedent.com

REGEDENT
smart regeneration



SHOW BIOFILM THE „RED“ CARD

ELIMINATION OF THE BIOFILM IS KEY FOR THE TREATMENT SUCCESS OF PERIODONTITIS, PERI-IMPLANT MUCOSITIS, AND PERI-IMPLANTITIS.



Art. 8131.902EN, 2018-01-01

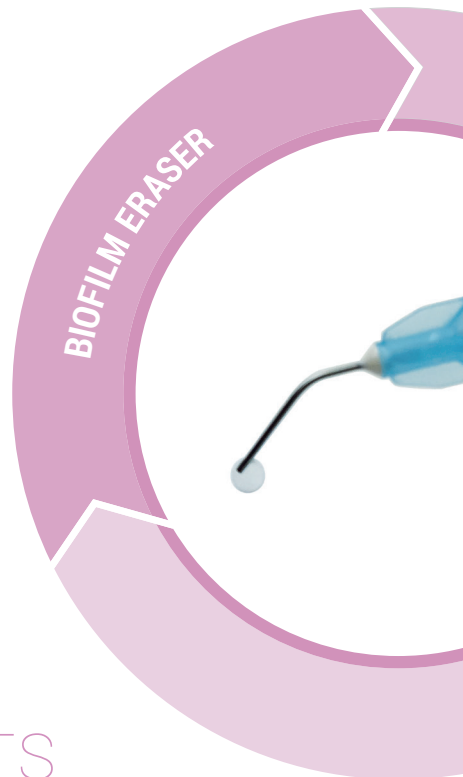


A NEW APPLICATION

FOR PERIODONTAL AND PERI-IMPLANT INFLAMMATION

Periodontitis, peri-implant mucositis and peri-implantitis are bacterial inflammations with similar symptoms. The underlying cause of all three indications, which progress in a similar way, is bacterial plaque forming a biofilm, rich in pathogenic bacteria. The softening of the biofilm and effective elimination of the bacteria is the key prerequisite for successful treatment of these conditions.

PERISOLV® is a new cleaning gel used in addition to mechanical debridement.



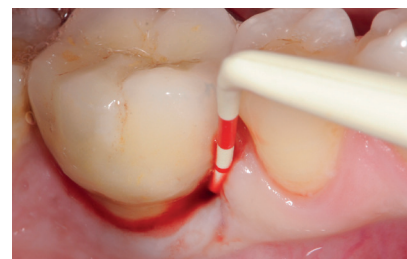PERISOLV®-EFFECTS

- ELIMINATION OF THE BIOFILM*
- IMPROVED MUCOSITIS TREATMENT¹
- REDUCTION OF POCKET DEPTH EVEN IN PERSISTENT POCKETS^{2,3}

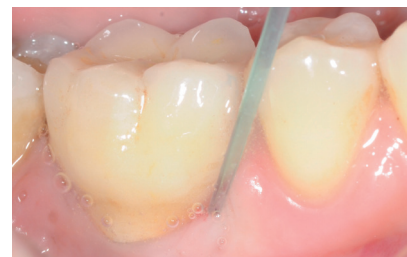* Enhancing bacterial removal by mechanical debridement.

TREATMENT OF PERI-IMPLANTMUCOSITIS

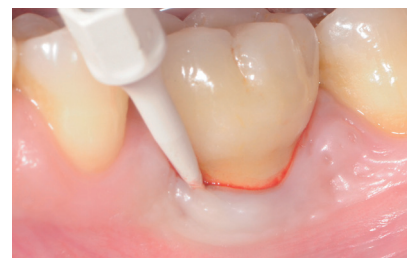CASE BY PROF. VINCENZO IORIO-SICILIANO, UNIVERSITY OF CATANZARO, ITALY



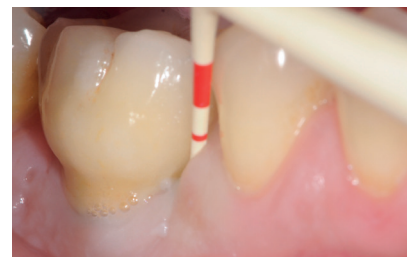Implant with probing depth (PD) \leq 5mm and BOP⁺.



Application of PERISOLV® before non-surgical treatment.



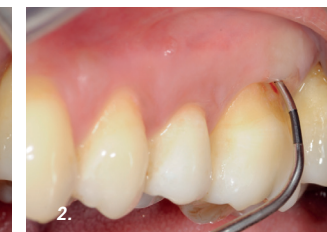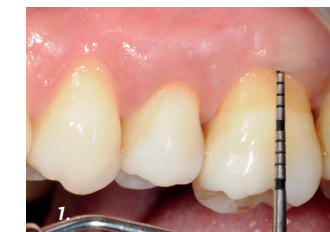Biofilm removal using a sonic scaler with PEEK tip.



6 MONTHS AFTER TREATMENT
Probing depth (PD) after 6 months observation time.

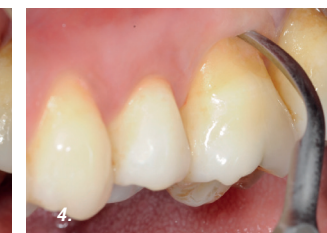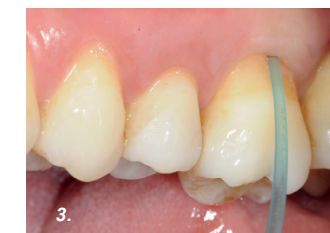TREATMENT OF A FURCATION DEFECT

CASE BY PROF. VINCENZO IORIO-SICILIANO, UNIVERSITY OF CATANZARO, ITALY



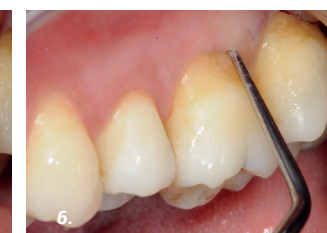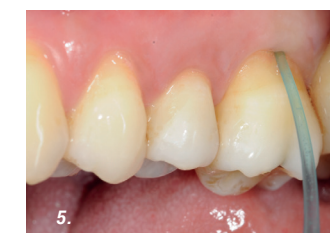1. A PD of 5 mm was noted.

2. A class-II furcation defect was recorded.



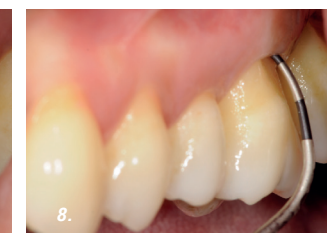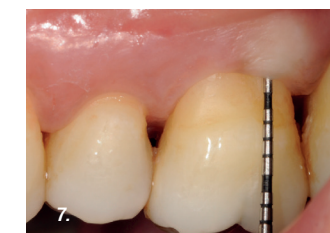3. First application of PERISOLV®.

4. Scaling was performed using an ultrasonic device.



5. Second application of PERISOLV®.

6. Root planing was performed.



6 MONTHS AFTER TREATMENT

7. A PD of 3 mm was reported.

8. A class-I furcation defect with BOP⁻ was recorded.