

PARADENT

hyadENT BG

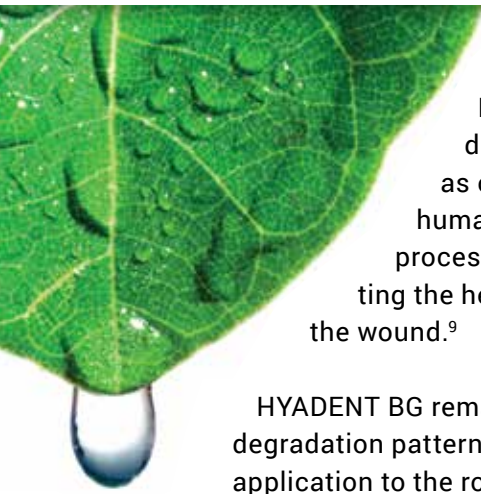
Hyaluronic Acid

THE NATURAL PROMOTER OF
REGENERATION



HYADENT BG

THE NATURAL PROMOTER OF REGENERATION



HYADENT BG, a highly concentrated and cross-linked hyaluronic acid gel, is designed specifically for the application in the dental field. Hyaluronic acid (HA), as one of the main components of the extracellular matrix is naturally present in the human body.¹⁻³ Studies have shown that prolonged presence of HA during the healing process promotes healing by regeneration rather than reparation.^{4,5} Besides accelerating the healing of soft tissue and bone,^{6,7,8} the bacteriostatic properties of HA also protect the wound.⁹

HYADENT BG remains present throughout the various phases of the healing process due to its slow degradation pattern (several weeks).¹⁰ In addition, it aids the surgical periodontal treatment after application to the root surface and soft tissue. This leads to faster wound closure, substantial pocket reduction and enhanced attachment.¹¹⁻¹³ When mixed with bone substitute material of any origin HYADENT BG forms an easily manageable putty, which may in addition lead to accelerated bone formation.^{14,15}

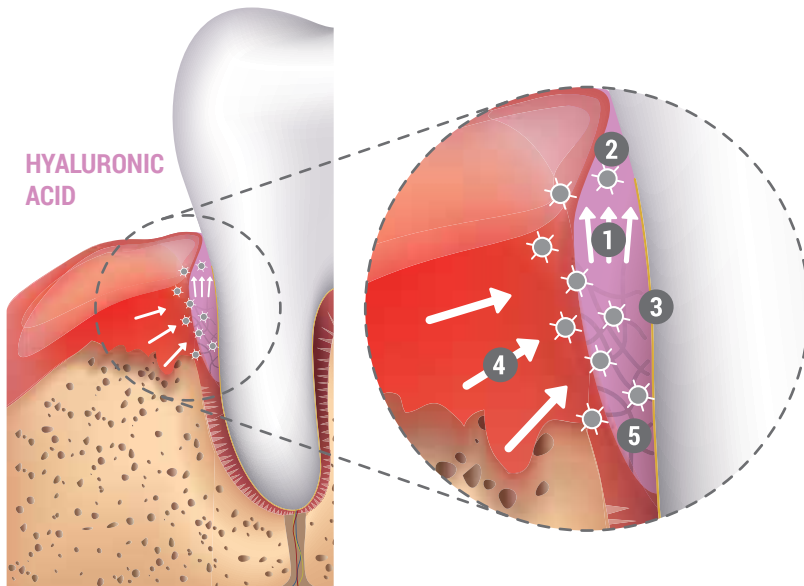
HYALURONIC ACID-EFFECTS

HYADENT BG is a hyaluronic acid-based treatment solution of non- animal origin optimized for regenerative dental and periodontal applications.

- **ACCELERATED TISSUE HEALING**
COORDINATES THE POST-OPERATIVE INFLAMMATION PROCESS AND ACCELERATES NEOANGIOGENESIS^{11,16}
- **IMPROVED OUTCOME**
STABILIZES COAGULUM AND SUPPORTS TISSUE REGENERATION^{11-13,16}
- **IMPROVED PREDICTABILITY**
BACTERIOSTATIC ACTION AND REDUCED PATHOGEN PENETRATION⁹



HYALURONIC ACID-MODE OF ACTION



- 1 ATTRACTS BLOOD
- 2 STABILIZES COAGULUM AND SUPPORTS TISSUE REGENERATION
- 3 BACTERIOSTATIC EFFECT PROVIDES PROTECTION
- 4 GROWTH FACTORS ATTRACTED BY HYALURONIC ACID
- 5 COORDINATES INFLAMMATION AND ACCELERATES NEO-ANGIOGENESIS

TREATMENT OPTIONS

NON-SURGICAL PROCEDURES:

Successive treatment after Scaling and Root Planing (SRP)



SURGICAL PROCEDURES:

Recession coverage with the Coronally Advanced Flap (CAF) technique¹¹⁻¹³



Recession coverage with Connective Tissue Graft (CTG) or Free Gingival Graft (FGG)¹¹⁻¹³



Infrabony defects⁶⁻⁸



Bone grafting (mixed with bone graft material)^{14, 15}



Oral wound healing⁹



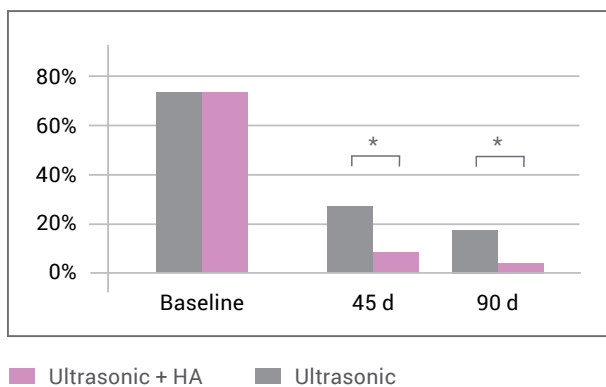
Bone graft material granules mixed with HYADENT BG provides exceptional handling characteristics.

IMPROVED PREDICTABILITY

BACTERIOSTATIC ACTION AND REDUCED PATHOGEN PENETRATION

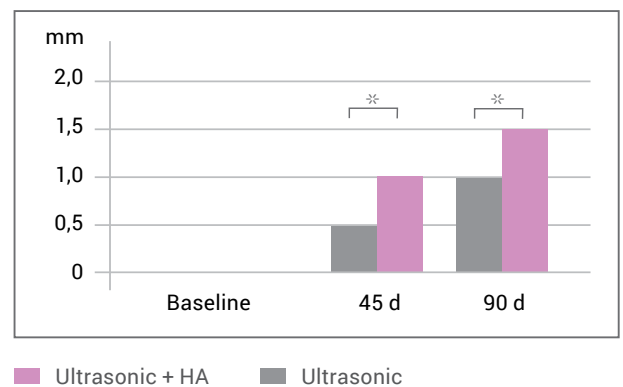
The bacteriostatic properties of HA support tissue regeneration.⁹ The use of HA during surgical and non-surgical periodontal treatment may also improve periodontal parameters.^{17,18} It has been shown, that periodontal therapy supported by HA leads to an increased level of bone formation.¹⁹ In addition, when used in combination with ultrasonic Scaling and Root Planing (SRP) HA has a beneficial effect on the outcome of non-surgical periodontal procedures.¹⁷

REDUCTION OF BLEEDING ON PROBING (BOP)¹⁷



The application of hyaluronic acid after ultrasonic treatment significantly reduced BOP from 72.7% to 4.5% at 90 days after treatment.¹⁷

REDUCTION OF PROBING POCKET DEPTH (PPD)¹⁷



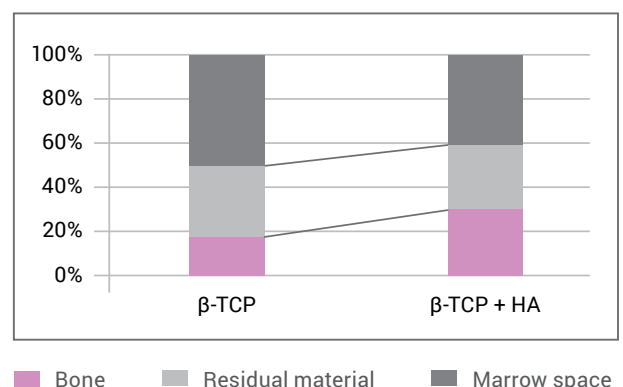
A significant reduction of the probing pocket depth was observed with a mean PPD reduction of 1.5 mm after 90 days.¹⁷

ACCELERATED BONE FORMATION^{7,8,14,20}

OPENING THE DOOR TO NOVEL THERAPEUTIC ALTERNATIVES

HA is an attractive material to be combined with resorbable bone graft materials such as β -tricalcium phosphate (β -TCP). Six months after sinus floor augmentation procedures, the putty combining β -TCP granules and HA (β -TCP + HA) led to a significantly higher amount of bone and smaller marrow space compared to β -TCP granules alone.¹⁴ The increased osteogenic potential observed with the β -TCP + HA was attributed to the physicochemical and biological properties of HA. In addition, the β -TCP + HA putty had better surgical handling properties and was easier to compact into the designated defect.¹⁴

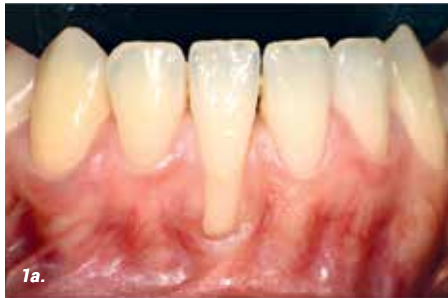BONE QUALITY¹⁴



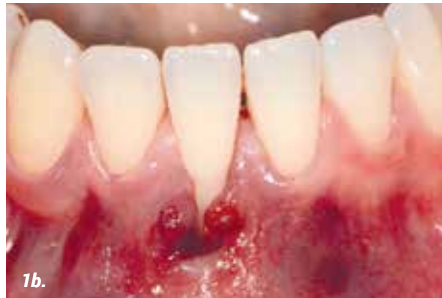Six months after sinus floor augmentation β -TCP + HA led to a significantly increased amount of bone and reduced marrow space compared to β -TCP granules alone.¹⁴

DEEP MILLER CLASS II RECESSION

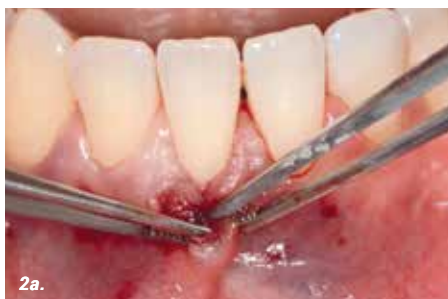CLINICAL CASE PROVIDED BY PROF ANTON SCULEAN, UNIVERSITY OF BERNE, SWITZERLAND



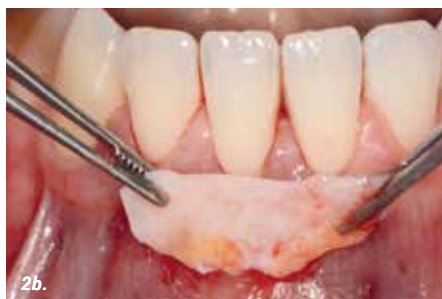1a. Baseline



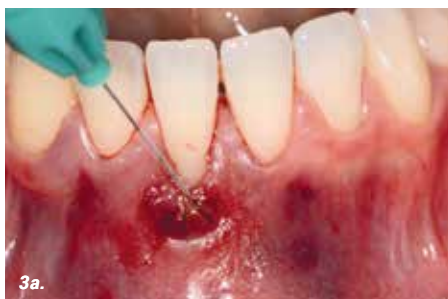1b. Tunnel



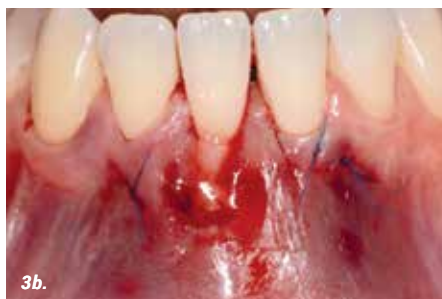2a. Mobilized tunnel



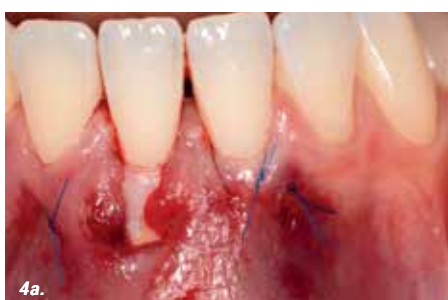2b. Connective tissue graft (CTG)



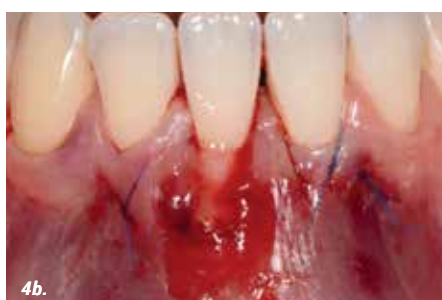3a. Application of HYADENT BG.



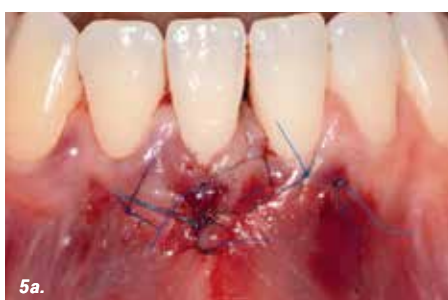3b. Applied HYADENT BG in the tunnel.



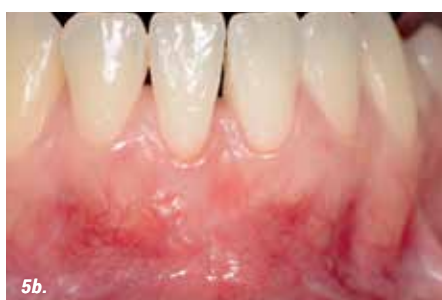4a. Connective tissue graft fixed in the tunnel.



4b. Repeated application of HYADENT BG on the connective tissue graft.



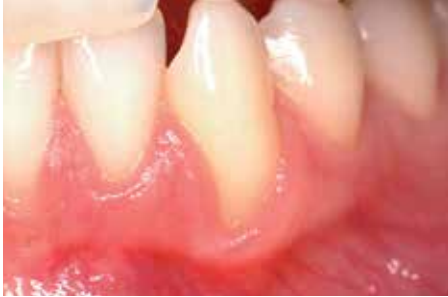5a. Laterally closed tunnel.



5b. Outcome after 6 month.

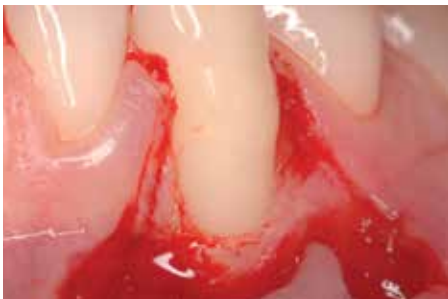TREATMENT OF A GINGIVAL RECESSION

CLINICAL CASE PROVIDED BY PROF ANDREA PILLONI, ROME, ITALY



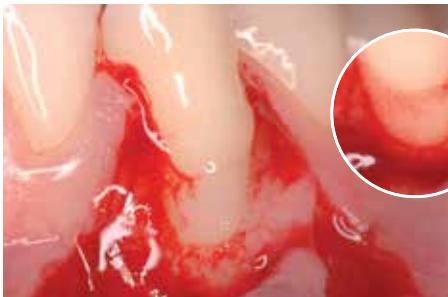
PRE-OPERATIVE

A recession defect of Miller Class II was observed at the lower right canine despite the patient's good dental hygiene and regular dental treatment.

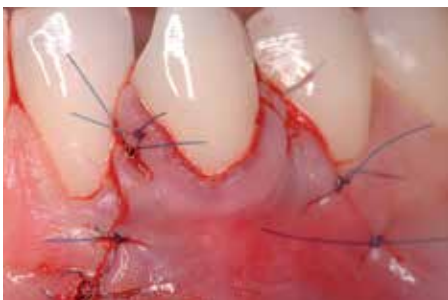

SURGERY

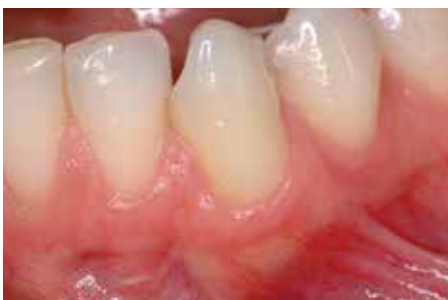The recession was treated surgically. After flap preparation, the root surface was carefully cleaned.



HYADENT BG was applied on to the root surface and incision areas of the soft tissue to support periodontal regeneration and fast wound healing (large image). HYADENT BG mixes well with the blood, which is essential for the clinical efficacy of hyaluronic acid (small image).



The wound was closed with a Coronally Advanced Flap (CAF).

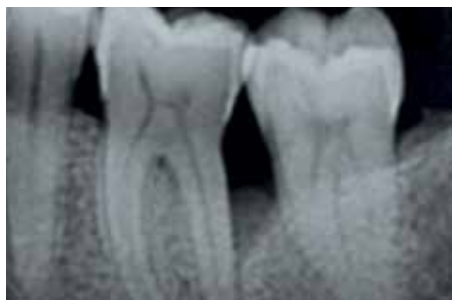

1 YEAR POST-OPERATIVE

The recession remains well covered with healthy soft tissue.

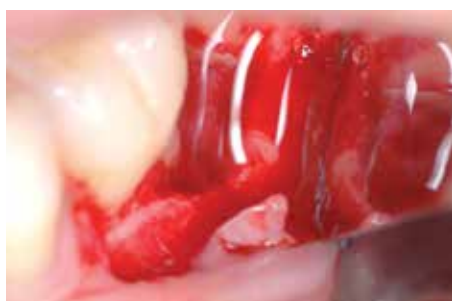SURGICAL TREATMENT OF AN INFRABONY DEFECT

CLINICAL CASE PROVIDED BY PROF ANDREA PILLONI, ROME, ITALY



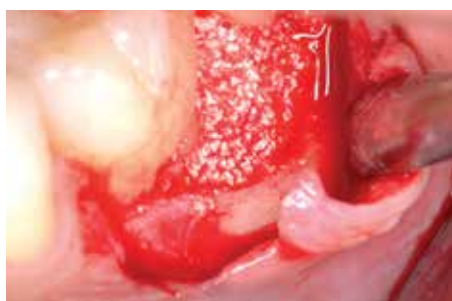
PRE-OPERATIVE

A deep infrabony defect could be detected on the x-ray and by probing.

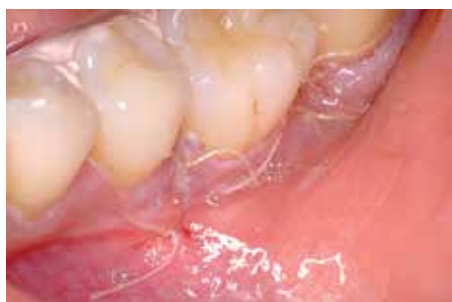

SURGERY

The defect site was opened and cleaned. HYADENT BG was applied directly to the root surface allowing stabilization of the clot.

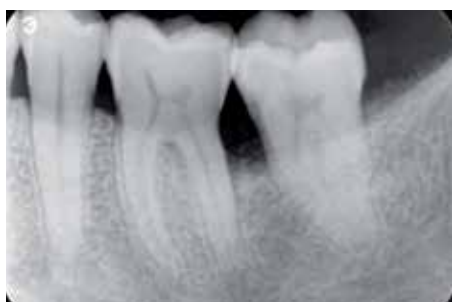

The defect was filled with bone graft material and covered with HYADENT BG.



72 HOURS POST-OPERATIVE

The application of HYADENT BG between the graft material and the covering soft tissue led to accelerated wound healing. The wound was closed at this early stage.



12 MONTHS POST-OPERATIVE

Radiographic analysis of the site 12 months after treatment shows solid bone structures and a closure of the infrabony defect.

AVAILABLE PRODUCTS

ARTICLE NUMBER	SIZE
<div>hyadENT BG</div> BS091	HA Gel composed of a mixture of cross-linked (1,6%) and natural (0,2%) Hyaluronic Acid 2 x 1.2 ml cylindrical ampulla
<div>hyadENT</div> BS065	Natural Hyaluronic Acid Gel (1,4% HA) 1 x 1.0 ml syringe



REFERENCES

1. Lee JY, Spicer AP. 'Hyaluronan: a multifunctional, megadalton, stealth molecule.' Curr Opin Cell Biol 2000;12:581–586.
2. McDonald J, Hascall VC. 'Hyaluronan mini review series.' J Biol Chem 2002; 277:4575–4579.
3. Jiang D et al. 'Hyaluronan as an immune regulator in human diseases.' Physiol Rev 2011;91:221–264.
4. Longaker T et al. 'Studies in Fetal Wound Healing: V. A prolonged presence of hyaluronic acid characterizes fetal wound healing' Ann. Surg. 1991; April:292–296.
5. Mast BA et al. 'Hyaluronic Acid Modulates Proliferation, Collagen and Protein Synthesis of Cultured Fetal Fibroblast' Matrix, 1993;13:441–446.
6. Salbach J et al. 'Regenerative potential of glycosaminoglycans for skin and bone.' J Mol Med 2012;90:625–635.
7. Muzafer A. et al. 'The Effect of Hyaluronic Acid-supplemented Bone Graft in Bone Healing: Experimental Study in Rabbits' J Biomater Appl 2006 20:209
8. Sasaki T, Watanabe C, Bone. Vol. 16. No.1 January 1995:9-15
9. Pirnazar P. et al. 'Bacteriostatic effects of hyaluronic acid.' Journal of Periodontology 1999;70:370-374
10. De Boule K, Glogau R, Kono T, et al. 'A Review of the Metabolism of 1,4-Butanediol Diglycidyl Ether–Crosslinked Hyaluronic Acid Dermal Fillers.' Dermatologic Surgery 2013;39(12):1758-1766
11. King SR, Hickerson WL, Proctor KG. Beneficial actions of exogenous hyaluronic acid on healing. Surgery 1991;109(1):76-84
12. Fawzy ES. et al. Local application of hyaluronan gel in conjunction with periodontal surgery: a randomized controlled trial. Clin Oral Invest 2012;16:1229-1236
13. Briguglio, F. et al. Treatment of infrabony periodontal defects using a resorbable biopolymer of hyaluronic acid: A randomized clinical trial. Quintessence Int 2013;44:231-240
14. Stiller M. et al. 'Performance of β -tricalcium phosphate granules and putty, bone grafting materials after bilateral sinus floor augmentation in humans' Biomaterials 2014;35(10):3154-3163.
15. Mendes RM et al. 'Sodium hyaluronate accelerates the healing process in tooth sockets of rat' Arch Oral Biol 2008;53:1155–1162
16. Kessiena L. Aya et al. 'Hyaluronan in wound healing: Rediscovering a major player.' Wound Rep Reg 2014;22:579-593.
17. Bevilacqua, L. et al. 'Effectiveness of adjunctive subgingival administration of amino acids and sodium hyaluronate gel on clinical and immunological parameters in the treatment of chronic periodontitis.' Annali di Stomatologia (Roma) 2012;3:75-81.
18. Johannsen A. et al. 'Local Delivery of Hyaluronan as an Adjunct to Scaling and Root Planing in the Treatment of Chronic Periodontitis' J Periodontol 2009;80:1493-1497.
19. Bertl, K. et al. 'Hyaluronan in non-surgical and surgical periodontal therapy: a systematic review.' J Clin Periodontol 2015;42:236-246.
20. Shamma et al. 'Evaluation of the effect of hyaluronic acid mixed with bisphasic calcium phosphate on bone healing around dental implants. Alexandria Dental Journal. (2017) Vol.42:104-11.

HYADENT BG is a registered brand and manufactured by BioScience GmbH, Walsmühler Str. 18, 19072 Dummer, Germany

CE certified medical device, class III Art. 8161.900EN, Version 2018-04

